

PATIENT

Milo Fontana

SPECIES

Canine

BREED

Maltese Mix

SEX

MN

AGE

7

WEIGHT

12

INTERPRETED BY

Eric Lindquist, DMV
DABVP, Cert. IVUSS

IMAGING PERFORMED BY

Jenn

HOSPITAL NAME

Rockaway Animal
Hospital

REFERRING VET

Dr Maniar

INVOICE

24748

DATE

05/08/2026

PRESENTING CLINICAL SIGNS

re check from 5/7 Dog has been fasted was offered food last night and did not eat

LIMITED ULTRASONOGRAPHIC EXAMINATION OF THE ABDOMEN

Gastrointestinal

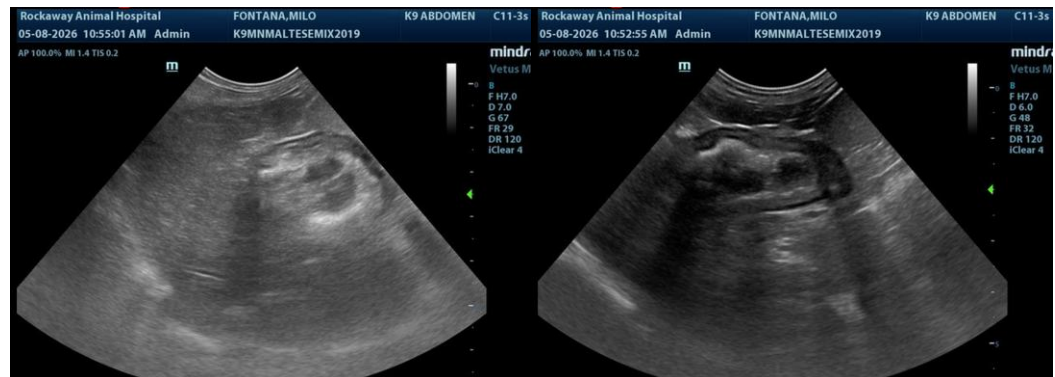The stomach in this patient revealed minimal residual ingesta and hypoechoic structures. No obstructive pattern. However, delayed outflow may be an issue. Small intestine and colon were unremarkable.

ULTRASONOGRAPHIC FINDINGS

- Minimal residual luminal content in the upper GI.
- Stomach- no evidence of structural disease.

INTERPRETATION OF THE FINDINGS & FURTHER RECOMMENDATIONS

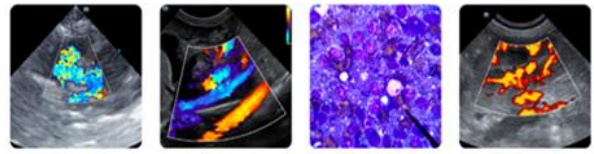
If the patient was truly NPO, then endoscopy would be indicated. Otherwise, GI protective protocol with continual medical management indicated. The material in the stomach was minimal and most consistent with foodstuff +/- medications. However, small foreign body is possible



The information and recommendations provided are based on the images presented by the referring veterinarian/sonographer. No evaluation can be communicated regarding pathology that was not visible in the image/video clips provided.

Thank you for this referral. If the clinical or image interpretation does not parallel your findings or if I can be of any further assistance, please contact me.

Eric Lindquist, DMV, DABVP(CFM), Cert. IVUSS,
CEO, Owner, Founder -- SonoPath.com



PATIENT

info@SonoPath.com

Milo Fontana

SPECIES

Canine

BREED

Maltese Mix

SEX

MN

AGE

7

WEIGHT

12

INTERPRETED BY

Eric Lindquist, DMV
DABVP, Cert. IVUSS

**IMAGING
PERFORMED BY**

Jenn

HOSPITAL NAME

Rockaway Animal
Hospital

REFERRING VET

Dr Maniar

INVOICE

24748

DATE

05/08/2026